

Percutaneous Atrial Septal Closure in Immunocompromised Patients

Subrata Kar, DO¹, Jamil Aboulhosn, MD², Anwar Tandar, MD³, Rubine Gevorgyan, MD¹, Nicholas Miller, MS¹, Jonathan M. Tobis, MD, MSCAI^{1*}

¹ Program of Interventional Cardiology, David Geffen School of Medicine, University of California at Los Angeles, Los Angeles, California, USA

² Division of Cardiology, David Geffen School of Medicine, University of California at Los Angeles, Los Angeles, California, USA

³ Division of Cardiovascular Medicine, University of Utah School of Medicine, Salt Lake City, Utah, USA

Abstract

Background: Percutaneous closure devices for cardiac defects have been used with a high degree of efficacy and safety. However, patients with autoimmune disease or immunosuppression are excluded in clinical trials due to their presumed higher risk. Percutaneous closure of patent foramen ovale (PFO) or atrial septal defect (ASD) is safe in patients who are immunosuppressed or have autoimmune disease.

Methods: A retrospective observational multicenter study was performed including 24 patients who were immunocompromised or had autoimmune disease from vasculitis, Human Immunodeficiency Virus, hepatitis, cancer, or renal transplant and underwent percutaneous PFO or ASD closure for cryptogenic stroke (9.38%), desaturation (5.21%), migraine (7.29%), or a combination of these diagnoses (3.13%). Post-procedure follow-up included clinical evaluation at 3–6 months or telephone questionnaire up to 8 years later.

Results: Of the 24 patients who met inclusion criteria (53 ± 14 years of age, follow-up of 21 ± 28 months), 19 had a PFO (79%), 5 had an ASD (21%), and 21 (88%) underwent closure. There was no evidence of endocarditis, device erosion, exacerbation of migraine, or recurrent stroke. Only one patient (4%) experienced a transient neurologic deficit after closure due to complex migraine with visual aura. Mortality status, which was verified by the social security death index, showed five deaths related to non-cardiac conditions.

Conclusion: This observational study of an uncommon

condition suggests that percutaneous closure of a PFO or ASD is safe in immunocompromised patients.

Copyright © 2017 Science International Corp.

Key Words

Percutaneous closure • Immunocompromised • Atrial septal defect • Patent foramen ovale • Stroke • Migraine

Introduction

Intra-cardiac defects such as patent foramen ovale (PFO) and atrial septal defect (ASD) are often closed off-label for cryptogenic stroke, migraine, or hemodynamically significant ASD. The incidence of device-related infection in patients with normal immune systems who undergo closure is exceedingly rare. In a retrospective survey of PFO closure device explantation, only 38 devices were explanted for various reasons out of 13,736 cases (0.28%), with only one explanted due to endocarditis [1]. Some risk factors may predispose patients to greater risk of infection of a closure device, such as diabetes, renal failure, organ transplant, immunosuppressed state, or autoimmune disease. The safety of PFO or ASD closure in patients who are immunocompromised or have an autoimmune disorder is unknown because patients with these conditions are excluded from randomized



clinical trials. Therefore, this study was a retrospective observational analysis of percutaneous PFO or ASD closure in immunocompromised patients to determine safety with respect to infective endocarditis or erosion.

Materials and Methods

We conducted a retrospective observational study of patients at two tertiary care centers in the United States that perform a high volume of percutaneous closure procedures. The centers' databases were reviewed to identify any immunocompromised or autoimmune disease patients who had received a PFO or ASD closure device.

Patients were informed of the investigational and non-FDA-approved indication for PFO closure, and they desired closure for prevention of future strokes, complex migraine with transient visual neurologic deficit, or recurrence of migraine headaches. Informed and written consent was obtained from all patients.

Based upon operator preference, all patients received pre- or post-procedural antibiotics (cefazolin, clindamycin, levofloxacin, or vancomycin as the sole agent) up to 48 hours after closure. Patient outcomes were assessed via 3–6-month clinical follow-up or phone questionnaire up to eight years later (mean 21 ± 28 months) consisting of questions pertaining to migraines, palpitations, chest pain, infections, closure complications post-procedure, worsening or improvement in migraines, post-closure stroke, and general health condition post-closure. For patients who were unreachable for phone interview, mortality status was verified by the social security death index.

Results

Our total patient population ($n = 1,303$) consisted of 908 PFO (69.7%) and 395 ASD (30.3%) patients, of which only 24 patients (1.8%) met our inclusion criteria. These 24 immunocompromised patients were identified from October 2002 to September 2014 and had systemic lupus erythematosus, rheumatoid arthritis, mixed connective tissue disease, non-specific connective tissue disease, scleroderma, end-stage renal disease post-renal transplant, Sjogren's syndrome,

hepatitis A, hepatitis C, or human immunodeficiency virus (HIV). They were treated with various immunosuppressants and had a PFO or ASD. PFO or ASD were documented by transesophageal echocardiography, transthoracic echocardiography, or transcranial doppler evaluation. Patients were referred for PFO or ASD closure due to a history of previous stroke, complex migraine with transient visual neurologic deficit, desaturation, or migraines (with or without aura) in isolation or as a combination of events ($n = 21$, 87.5%). Other closure indications included chest pain ($n = 1$, 4.2%), pre-liver transplant work-up ($n = 3$, 12.5%), and pulmonary embolism with right heart failure ($n = 1$, 4.2%). Immunosuppressant medications included prednisone, mycophenolate mofetil, methotrexate, leucovorin, cyclophosphamide, azathioprine, hydroxychloroquine sulfate, leflunomide, rituximab, chemotherapeutic agents (folfinrox, gemcitabine, and other unspecified agents), ritonavir, emtricitabine/tenofovir disoproxil (HIV combination medication), elvitegravir/cobicistat/emtricitabine/tenofovir/disoproxil (HIV combination medication), or darunavir as sole agents or in various combination regimens.

Of the 24 patients (53 ± 14 years of age), 19 had a PFO (79.1%), 5 had an ASD (20.8%), and 21 underwent closure (87.5%). Two patients (8.3%) declined percutaneous closure and were lost to follow-up. Both had obstructive sleep apnea with hypersomnia, which is associated with increased risk of right-to-left shunting in the presence of a PFO [2, 3]. During cardiac catheterization, one patient (4.2%) was deemed an inappropriate candidate for closure secondary to pulmonary hypertension from scleroderma and was referred for lung transplant evaluation. All PFO or ASD closure procedures were successful. Figure 1 shows the proportion of PFO and ASD patient groups. All patients with autoimmune disorders were treated with single or combination immunosuppressive drug regimens, leading to an immunocompromised state.

No periprocedural complications occurred during closure. One patient (4.2%) experienced a transient neurologic deficit during follow-up associated with lightheadedness, scintillating scotoma, and severe headache, which was diagnosed as complex migraine with visual aura. No patient reported endocarditis, device erosion, exacerbation of migraine, or recurrent stroke. Of the seven patients (29.2%) who

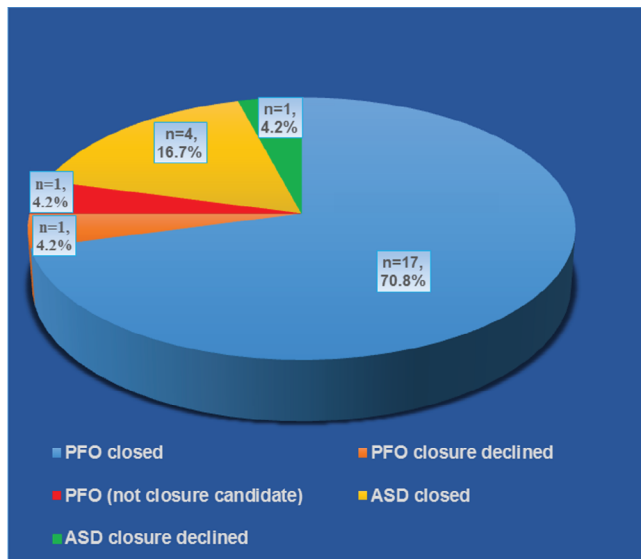


Figure 1. Patent foramen ovale and atrial septal defect patient groups (21 patients underwent closure; two declined closure; one not a closure candidate).

had migraine prior to closure, five (71.4%) reported resolution of migraines. There were five deaths (20.8%); three were due to non-cardiac conditions (one of these patients did not receive a device), one was associated with metastatic pancreatic cancer, and one was due to unknown causes in a 77-year-old woman who did not receive a device. [Table 1](#) shows closure indications and patient outcomes.

Discussion

As patients who are immunocompromised or have an autoimmune disease are at higher risk of developing an infection [4, 5, 6], there is a concern that implanting a permanent foreign body in the vasculature might increase their risk of developing endocarditis. In addition, the healing process in these patients may be compromised, and some devices could be associated with a higher risk of erosion through a thin atrial wall. However, there are no data published regarding the use of cardiac devices in this patient population because these patients are specifically excluded from prospective randomized trials of new devices to diminish the risk of complications that could make the device appear unsafe upon review by the FDA. Nevertheless, clinical indications for closure of ASD

or PFO may arise in immunocompromised patients. Thus, the purpose of this retrospective observational study was to determine whether there is increased risk in immunocompromised patients who have an implanted closure device.

Although this was a small patient population (24 out of 1,303 cases) with a relatively rare combination of disorders, it is encouraging to note that there were no severe complications reported, such as increased risk of endocarditis or erosion of the device.

The occurrence of device infection after percutaneous PFO or ASD closure is extremely uncommon. A few case reports have described the occurrence of endocarditis from a PFO or ASD device, which commonly necessitates surgical explantation [7, 8, 9]. One case describes successful treatment achieved solely with antibiotics [10]. However, no observational or randomized controlled studies have been performed for infections associated with septal closure devices.

Other implantable therapeutic foreign bodies in patients with normal immune function, such as pacemakers or implantable cardioverter defibrillators, are more prone to infections (1–6%), which increases the risk of mortality even after successful treatment of the infection [11, 12, 13]. Pacemaker infection rates from the 1970s to 1980s were even higher (1–19.9%) [14].

Our study patients received medications that are known to suppress the immune system and had various medical conditions that predisposed them to an immunocompromised state ([Table 1](#)). Autoimmune disease also may induce a prothrombotic state promoting stroke, such as an HIV patient with protein C and protein S deficiency who developed a stroke in the presence of a PFO [15]. The prevalence rates of anti-cardiolipin antibodies in patients with ischemic strokes were 17–21% [16]. A retrospective case series of 40 patients showed that anti-phospholipid antibodies and hypercoagulability is common in patients with PFO [17]. A case-controlled study also showed that anti-phospholipid antibodies are strongly associated with PFO and atrial septal aneurysms [18]. Hence, autoimmune diseases with various hypercoagulable factors may increase the risk of stroke, which may be reduced with PFO closure. Of the patients in our study, one had anti-phospholipid antibodies with Sjogren's syndrome and another had anti-cardiolipin antibodies with systemic lupus erythematosus. Both patients developed a

Table 1. PFO and ASD closure indications and outcomes (n = 24)

Patient	Closure Indication	Device	Size (mm)	Complications	Residual Shunt (TEE/TCD/ICE)	Post-Procedure Symptoms	Post-Procedure Follow-Up (months)
1	Stroke	Cardioseal	28	None	Trace (TEE)	None	2
2	Desaturation	Amplatzer	35	None	No (TEE)	None (died, non-cardiac etiology)	89
3	Desaturation	Amplatzer	Unspecified	None	Small (TEE)	None (died, non-cardiac etiology)	47
4	Stroke, Desaturation	No closure (PHTN, referred for lung transplant evaluation)	N/A	N/A	N/A	N/A (died, non-cardiac etiology)	7
5	Stroke	Amplatzer	35	None	Moderate (TEE)	None	3
6	Migraine without area, orthodexia-platypnea	Cribiform	35	None	No (TEE)	Migraine and orthodexia-platypnea resolved	3
7	Migraine without aura	Helex	25	None	No (ICE)	Migraine resolved	62
8	Migraine (ocular)	Helex	25	None	No (TEE)	Migraine resolved, transient neurologic deficit	57
9	Stroke	Helex	25	None	No (TEE)	None	3
10	Stroke, migraine with aura, TIA	Helex	25	None	No (TEE)	None	None
11	Migraine without aura	No closure (patient declines)	N/A	N/A	N/A	N/A	2
12	Migraine with aura	Helex	25	None	No (TEE)	Migraine resolved	50
13	Desaturation	Amplatzer	15	None	No (ICE)	None	None
14	Stroke	Amplatzer	6	None	No (TEE)	None (died, pancreatic cancer with metastasis on chemotherapy)	None
15	Stroke	Helex	25	None	Yes (ICE)	None	1
16	Chest pain	Cribiform	35	None	No (ICE)	Unknown	None
17	Pre-liver transplant evaluation	Helex	25	None	No (TEE)	None	3
18	Stroke	Helex	25	None	No (ICE)	None	None
19	Stroke	Amplatzer	14	None	No (TEE)	Musculoskeletal chest pain	3
20	Pre-liver transplant evaluation	Cribiform	25	None	No (TEE)	None	3
21	Pre-liver transplant evaluation	Helex	25	None	No (TEE)	None	6

(Continued)

Table 1 (Continued). PFO and ASD closure indications and outcomes (n = 24)

Patient	Closure Indication	Device	Size (mm)	Complications	Residual Shunt (TEE/TCD/ICE)	Post-Procedure Symptoms	Post-Procedure Follow-Up (months)
22	Pulmonary embolism with right heart failure	Helex	30	None	No (TEE)	None	1
23	Right atrial and right ventricular enlargement	No closure (patient declined)	N/A	N/A	N/A	N/A (died, unknown etiology)	None
24	Migraine with aura	Amplatzer	10	None	No (TEE)	Migraine resolved	3

PFO = patent foramen ovale; ASD = atrial septal defect; TEE = transesophageal echocardiography; TCD = trans-cranial Doppler; ICE = intracardiac echocardiography; PHTN = pulmonary hypertension; N/A = non-applicable; TIA = transient ischemic attack

stroke in the presence of a PFO. Conversely, the PFO in Cryptogenic Stroke Study and the Anti-Phospholipid Antibodies and Stroke study (PICSS-APASS) post-hoc retrospective analysis did not show an increased risk of stroke in patients with anti-phospholipid antibodies and PFO [19].

Our study has some limitations. This was a retrospective observational study of a complex but small patient population, which limits the generalizability of the results and prohibits adequate power for statistical analysis. Also, 10 out of the 21 patients (47.6%) underwent closure with the Helex device, which has not been associated with erosions. This fact may have diminished the risk of erosions even in an autoimmune population. Nevertheless, this study provides a small database on the use of device closure in these vulnerable patients, as no prior studies describe their treatment. This study was set at tertiary care centers with highly experienced operators who routinely perform PFO or ASD closures.

References

- Verma SK, Tobis JM. Explantation of patent foramen ovale closure devices: A multicenter survey. *JACC Cardiovasc Interv.* 2011;4:579-585. DOI: [10.1016/j.jcin.2011.01.009](https://doi.org/10.1016/j.jcin.2011.01.009)
- Kar S. Cardiovascular implications of obstructive sleep apnea associated with the presence of a patent foramen ovale. *Sleep Med Rev.* 2014;18:399-404. DOI: [10.1016/j.smrv.2014.02.002](https://doi.org/10.1016/j.smrv.2014.02.002)
- Johansson MC, Eriksson P, Dellborg M. The significance of patent foramen ovale: A current review of associated conditions and treatment. *Int J Cardiol.* 2009;134:17-24. DOI: [10.1016/j.ijcard.2009.01.049](https://doi.org/10.1016/j.ijcard.2009.01.049)
- Kafes H, Guray Y, Gucuk Ipek E. Management of cardiac device infections according to current data. *Anadolu Kardiyol Derg.* 2014;14:76-81. DOI: [10.5152/akd.2013.4843](https://doi.org/10.5152/akd.2013.4843)
- Klug D, Balde M, Pavin D, Hidden-Lucet F, Clementy J, Sadoul N, et al. Risk factors related to infections of implanted pacemakers and cardioverter-defibrillators: Results of a large prospective study. *Circulation.* 2007;116:1349-1355. DOI: [10.1161/CIRCULATIONAHA.106.678664](https://doi.org/10.1161/CIRCULATIONAHA.106.678664)
- Sohail MR, Uslan DZ, Khan AH, Friedman PA, Hayes DL, Wilson WR, et al. Risk factor analysis of permanent pacemaker infection. *Clin Infect Dis.* 2007;45:166-173. DOI: [10.1086/518889](https://doi.org/10.1086/518889)
- Aruni B, Sharifian A, Eryazici P, Herrera CJ. Late bacterial endocarditis of an Amplatzer atrial septal device. *Indian Heart J.* 2013;65:450-451. DOI: [10.1016/j.ihj.2013.06.002](https://doi.org/10.1016/j.ihj.2013.06.002)

In conclusion, this small observational study shows the safety of PFO or ASD closure in patients who are immunocompromised or have autoimmune disorders. Patients reported an improvement or resolution of debilitating migraine, and there was no recurrence of stroke after closure. In this high-risk patient population, there were no procedural complications, local or systemic infection, endocarditis on the implanted device, or complications such as erosion across a follow-up period of up to 8 years (mean of 21 months).

Conflict of Interest

The authors have no conflict of interest relevant to this publication.

[Comment on this Article or Ask a Question](#)

8. Doguet F, Leguillou V, Godin M. Infected amplatzer device. *J Card Surg.* 2011;26:75. DOI: [10.1111/j.1540-8191.2010.01139.x](https://doi.org/10.1111/j.1540-8191.2010.01139.x)
9. Zahr F, Katz WE, Toyoda Y, Anderson WD. Late bacterial endocarditis of an amplatzer atrial septal defect occluder device. *Am J Cardiol.* 2010;105:279-280. DOI: [10.1016/j.amjcard.2009.09.011](https://doi.org/10.1016/j.amjcard.2009.09.011)
10. Calachanis M, Carrieri L, Grimaldi R, Veglio F, Orzan F. Infective endocarditis after transcatheter closure of a patent foramen ovale. *Catheter Cardiovasc Interv.* 2004;63:351-354. DOI: [10.1002/ccd.20185](https://doi.org/10.1002/ccd.20185)
11. Sohail MR, Henrikson CA, Jo Braid-Forbes M, Forbes KF, Lerner DJ. Increased long-term mortality in patients with cardiovascular implantable electronic device infections. *Pacing Clin Electrophysiol.* 2015;38:231-239. DOI: [10.1111/pace.12518](https://doi.org/10.1111/pace.12518)
12. de Bie MK, van Rees JB, Thijssen J, Borleffs CJ, Trines SA, Cannegieter SC, et al. Cardiac device infections are associated with a significant mortality risk. *Heart Rhythm.* 2012;9:494-498. DOI: [10.1016/j.hrthm.2011.10.034](https://doi.org/10.1016/j.hrthm.2011.10.034)
13. Kearney RA, Eisen HJ, Wolf JE. Nonvalvular infections of the cardiovascular system. *Ann Intern Med.* 1994;121:219-230. PMID: 8017749
14. Thanavaro KL, Nixon JV. Endocarditis 2014: An update. *Heart Lung.* 2014;43:334-337. DOI: [10.1016/j.hrtlng.2014.03.009](https://doi.org/10.1016/j.hrtlng.2014.03.009)
15. Tomomasa R, Yamashiro K, Tanaka R, Hattori N. Cerebral infarction in an HIV-infected patient with combined protein S and C deficiency and a patent foramen ovale. *J Stroke Cerebrovasc Dis.* 2013;22:e650-c652. DOI: [10.1016/j.jstrokecerebrovasdis.2013.04.019](https://doi.org/10.1016/j.jstrokecerebrovasdis.2013.04.019)
16. Bushnell CD, Goldstein LB. Diagnostic testing for coagulopathies in patients with ischemic stroke. *Stroke.* 2000;31:3067-3078. PMID: 11108774
17. Dodge SM, Hassell K, Anderson CA, Keller J, Groves B, Carroll JD. Antiphospholipid antibodies are common in patients referred for percutaneous patent foramen ovale closure. *Catheter Cardiovasc Interv.* 2004;61:123-127. DOI: [10.1002/ccd.10754](https://doi.org/10.1002/ccd.10754)
18. Tanaka Y, Ueno Y, Miyamoto N, Shimada Y, Tanaka R, Hattori N, et al. Patent foramen ovale and atrial septal aneurysm can cause ischemic stroke in patients with antiphospholipid syndrome. *J Neurol.* 2013;260:189-196. DOI: [10.1007/s00415-012-6613-4](https://doi.org/10.1007/s00415-012-6613-4)
19. Rajamani K, Chaturvedi S, Jin Z, Homma S, Brey RL, Tilley BC, et al. Patent foramen ovale, cardiac valve thickening, and antiphospholipid antibodies as risk factors for subsequent vascular events: The PICSS-APASS study. *Stroke.* 2009;40:2337-2342. DOI: [10.1161/STROKEAHA.108.539171](https://doi.org/10.1161/STROKEAHA.108.539171)

Cite this article as: Kar S, Aboulhosn J, Tandar A, Gevorgyan R, Miller N, Tobis J. Percutaneous Atrial Septal Closure in Immunocompromised Patients. *Structural Heart Disease.* 2017;3(4):96-101. DOI: <https://doi.org/10.12945/j.jshd.2017.001.17>